Check for updates

Digestive Endoscopy 2022; ••: ••–•• doi: 10.1111/den.14425

Review

Current status of endoscopic full-thickness resection with the full-thickness resection device

Julius Mueller, Armin Kuellmer, Moritz Schiemer, Robert Thimme and Arthur Schmidt

Department of Medicine II, Medical Center, Faculty of Medicine, University of Freiburg, Freiburg, Germany

Endoscopic full-thickness resection (EFTR) using the full-thickness resection device (FTRD) is an integral part of diagnostic and therapeutic endoscopy. Since its market launch in Europe in 2014, its safety and effectiveness have been proven in numerous studies. Adaptations in design as well as new techniques, such as hybrid EFTR, expand the spectrum of the FTRD system. The following review is intended to provide an overview of the clinical application and current evidence of EFTR with the FTRD system.

Key words: EFTR, FTRD, nonlifting adenoma, subepithelial tumor, T1 carcinoma

INTRODUCTION

ENDOSCOPIC RESECTION OF colorectal lesions with conventional methods such as endoscopic mucosal resection (EMR) and endoscopic submucosal dissection (ESD) are limited to the mucosal and submucosal layer. While EMR is considered the standard technique for noninvasive (mucosal) neoplasms, ESD allows en bloc resection of more advanced lesions with suspected submucosal invasion. However, both techniques have limitations for resection of nonlifting lesions or tumors arising from deeper layers than the submucosa.[1]

Endoscopic full-thickness resection (EFTR) is an emerging technique allowing resection of lesions not amenable to conventional endoscopic methods.

The full-thickness resection device (FTRD; Ovesco Endoscopy, Tuebingen, Germany) was introduced in 2014 and is currently the only approved device for EFTR.[2] This review aims to give a comprehensive overview on the device, technique, indications, and current data on EFTR with the FTRD system.

DEVICE AND TECHNIQUE

THE FTRD SYSTEM was originally developed for use in the colorectum and is now available in several variations for different indications. It is a single use product, which can be mounted on standard endoscopes. It consists of a transparent plastic cap loaded with an over-the-scope clip and an integrated monofilament snare. The snare is not advanced through the working channel but rather runs at the outer surface of the endoscope under a plastic sheath. The colonic FTRD is suitable for conventional endoscopes having a diameter of 11.5–13.2 mm and a working channel diameter of at least 3.2 mm.

More recently, the FTRD system was further modified and approved for use in the upper gastrointestinal (GI) tract (gastroduodenal FTRD). In addition, with the smaller "diagnostic FTRD", a device for diagnostic resections in the colorectum is available (Fig. 1). Figure 2 illustrates the resection procedure.

COLORECTAL EFTR

Indications

THE FTRD CAN be used for various "difficult-to-resect" lesions in the colorectum. The most common indication for EFTR in the colorectum is nonlifting (mainly recurrent) adenomas. Other indications include early carcinomas (treatment naïve or re-resection), adenomas at difficult anatomic locations (appendiceal orifice, diverticulum), subepithelial tumors (SETs) and diagnostic resection in patients with suspected motility disorders.

Technical success and R0 resection

Since the initial description of the device, numerous case series and retrospective studies have been published to describe efficacy and safety of EFTR in the colorectum.[3–11]

Corresponding: Arthur Schmidt, Department of Medicine II, Medical Center, Faculty of Medicine, University of Freiburg, Hugstetter Straße 55, D-79106 Freiburg, Germany. Email: arthur.schmidt@uniklinik-freiburg.de

Received 25 May 2022; accepted 21 August 2022.

© 2022 The Authors. *Digestive Endoscopy* published by John Wiley & Sons Australia, Ltd on behalf of Japan Gastroenterological Endoscopy Society.
This is an open access article under the terms of the Creative Commons Attribution License, which permits use, distribution and reproduction in any medium, provided the original work is properly cited.

DEN Digestive Endoscopy For Gastroenterologists and Endoscopic Surgeons

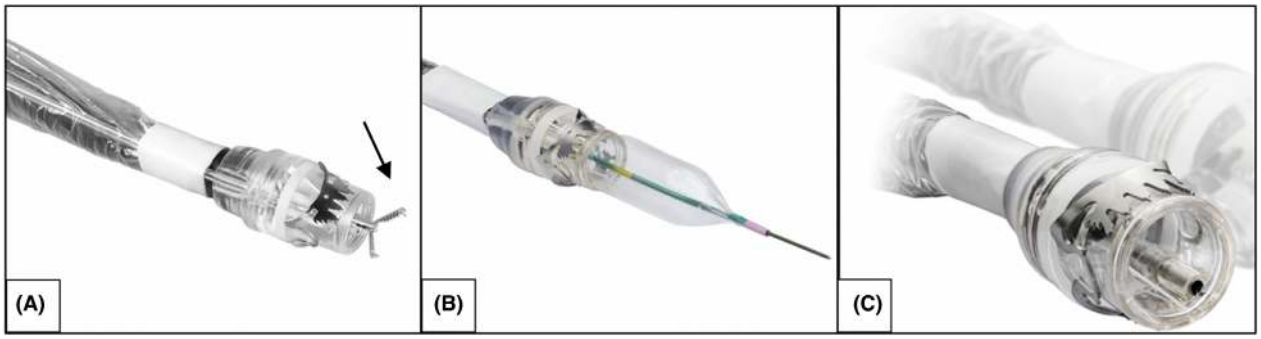

Figure 1 (A) Colonic full-thickness resection device (FTRD). The grasping forceps (arrow) is advanced through the working channel of the endoscope. It is used for retraction of the tissue into the cap. (B) Gastroduodenal FTRD. Compared to the colonic FTRD, the system has a smaller outer diameter (19.5 mm). It is further supplied with a 20 mm balloon and a guidewire to facilitate passage through the upper esophageal sphincter or the pylorus. If required, the guidewire is advanced beyond the upper esophageal sphincter under endoscopic vision. The balloon is then advanced until about 2/3 are outside of the cap. After inflation with air, the system can then be safely advanced. (C) Diagnostic FTRD. Compared to the colonic FTRD, the system has a smaller outer diameter (19.5 mm). In addition, the clip differs in tooth geometry and sling length for diagnostic indication.

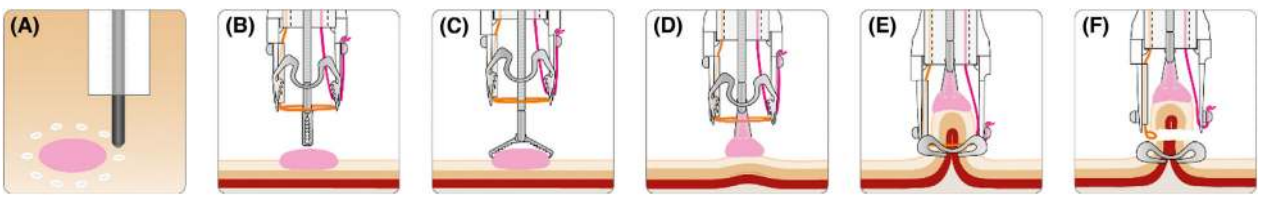

Figure 2 Schematic representation of the full-thickness resection device (FTRD) procedure. (A) Marking the lesion (marking probe). (B,C) Grasping the lesion (FTRD grasper). (D) Pulling tissue into the cap. (E) Clip application. (F) Closing the snare and high frequency resection.

Most studies have included various colorectal lesions with "difficult" adenomas being the most common indication. The first larger prospective multicenter study included 181 patients from nine German expert centers with various indications for EFTR in the colorectum (WALL RESECT study).[8] Primary outcome parameters were technical success (macroscopic complete en bloc resection) and R0 resection. Median lesion size was 15 mm (range, 2–30 mm). Technical success was achieved in 89.5% of cases and the R0 resection rate was 76.9%.

Two years later, results of the German colonic FTRD registry, the largest study on colorectal EFTR using the FTRD, were published.[4] In this registry 1178 patients from 65 academic and nonacademic centers were included; indications were very similar to those of the WALL RESECT study. Technical success was 88.2% with an R0 resection rate of 80%.

The results of the Dutch FTRD registry that included a total of 367 patients from 20 hospitals in the Netherlands were published in the same year. In contrast to the WALL RESECT study and the German FTRD registry, this study included a significantly higher proportion of T1 carcinoma. However, the results on technical success and R0 resection were very similar (83.9% and 82.4%, respectively).[10] These results are also in line with other larger retrospective studies on colorectal EFTR (Table 1).

Factors determining complete resection

Studies investigating factors determining resection completeness are scarce. Theoretically, R0 resection is mainly determined by the possibility to incorporate the target lesion into the cap. Due to the size of the cap, there is a natural physical limit concerning the amount of tissue it can capture. Early animal studies have shown that the maximum diameter of resection specimen in healthy porcine colon was 3.1–5.4 cm.[15] Most clinical studies on EFTR did not include lesions with a maximum diameter >30 mm.

Apart from lesion size, the ability to pull the lesion completely into the cap also depends on tissue characteristics (mobility of colonic wall, scarring, rigidity and volume of target lesion). In the WALL RESECT study, R0 resection was

© 2022 The Authors. *Digestive Endoscopy* published by John Wiley & Sons Australia, Ltd on behalf of Japan Gastroenterological Endoscopy Society.

Table 1 Colorectal full-thickness resection device (FTRD) literature ($N > 90$ patients)

Study	Study type	Total FTRD cases, *N*	Type of lesion	Technical success, %	R0 resection, %	Total AEs (major AEs) %
Andrisani *et al.* (2019)[3]	Retrospective multicenter	114	Residual/recurrent adenoma (39), incomplete resection at histology (26), suspected T1 carcinoma (16), therapy-naïve nonlifting (12), subepithelial lesions (10), diagnostic resection (3), adenoma involving the appendix (2), or diverticulum (2)	94.4	90	11 (2.3)
Schmidt *et al.* (2018)[8]	Prospective multicenter	181	Residual/recurrent adenoma (53), adenoma involving the appendix (34) or diverticulum (5), therapy-naïve nonlifting (32), subepithelial lesions (23), incomplete resection at histology (19), suspected T1 carcinoma (15)	89.5	76.9	9.9 (4.4)
Kuellmer *et al.* (2019)[12]	Retrospective multicenter	156	All histological adenocarcinoma: nonlifting lesions (92), incomplete resection of malignant polyp (64)	92.3	71.8	14.1 (3.9)
Meier *et al.* (2020)[4]	Retrospective multicenter	1178	Residual/recurrent adenoma (477), suspected T1 carcinoma (217), therapy naïve nonlifting (214) adenoma involving the appendix (89) or diverticulum (10), subepithelial lesions (80), diagnostic resection (16), other (75)	88.2	80	12.1 (3.1)
Zwager *et al.* (2020)[13]	Retrospective multicenter	367	Suspected T1 carcinoma (221), residual/recurrent adenoma (85), therapy naïve nonlifting (28) adenoma involving the appendix (15) or diverticulum (5), subepithelial lesions (13)	83.9	82.4	9.3 (2.7)
Krutzenbichler *et al.* (2021)[5]	Retrospective multicenter	229	Residual/recurrent adenoma (117), suspected/confirmed carcinoma (48), therapy naïve nonlifting (43), subepithelial lesions (18), dysplasia associated lesion (2), diagnostic resection (1)	83.8	77.2	16.2 (1.3)
Ichkhanian *et al.* (2022)[7]	Retrospective multicenter	95	Residual/recurrent adenoma (47), therapy naïve adenoma (16), subepithelial lesions (11), suspected T1 carcinoma (11), recurrent/residual adenocarcinoma (10)	84.2	82.7	5.3 (2.1)
Didden *et al.* (2022)[14]	Retrospective multicenter	136	Suspected T1 carcinoma (136)	87.5	79.7	6.6 (5.1)

AE, adverse event.

significantly lower for lesions >20 mm versus for lesions ≤20 mm. Although this finding could not be confirmed in other studies (e.g., the German FTRD registry), this also reflects our personal experience and is in concordance with the findings of a recently published meta-analysis on colorectal EFTR.[11] A recently published study from the Netherlands examining 136 FTRD interventions for suspected T1 carcinomas showed an R0 rate of 90% for lesions smaller than 15 mm. For lesions larger than 20 mm, no recommendation was made to use the FTRD system with low R0 resection rates.[14] Hence, especially in the presence of scarring or malignant histology, lesions >20 mm should not be selected for en bloc EFTR. Table 1 summarizes the largest studies published to date on the use of colorectal FTRD.

© 2022 The Authors. *Digestive Endoscopy* published by John Wiley & Sons Australia, Ltd on behalf of Japan Gastroenterological Endoscopy Society.

Adverse events/safety

Adverse events (AEs) after EFTR in the lower GI tract are reported in 5.3%[7] to 14.1%[12] of cases (Table 1) with 12.6% in the meta-analysis.[11] Definition of AE severity is inconsistent in available studies; the rate of severe AEs ranges from 1.3%[5] to 4.4%.[8] The most frequent complications are bleeding and perforation. Intraprocedural bleeding at the resection site is very rare, usually mild, and can easily be treated, for example, with coagulation. Delayed bleeding with requirement of re-intervention is reported in 0.0%[7] to 6.6%[5] of cases and can usually be treated sufficiently by standard endoscopic hemostatic methods. Acute perforation can occur during the procedure and is usually caused by a wrong sequence of resection steps. Most frequently, the tissue is resected although the clip is not properly released from the cap. Such perforations can be avoided by strict optical control of forward movement of the white ring, which is visible through the transparent cap during the procedure. In very rare cases, acute perforations can occur despite correct clip placement when the clip is not able to cover the entire resection area. While acute perforations may be closed endoscopically, secondary perforations usually require surgical treatment. The rate of perforation in the German FTRD registry was 2.5% (29 cases, 18 acute, 11 secondary) which is very similar to the rate reported in other larger studies (Table 1). The mechanism of secondary perforation is not fully understood. Similar to surgical anastomosis, in which anastomotic leakages are reported in around 5–8%, impaired defect healing may lead to delayed perforations. The risk of secondary perforation may be increased by known risk factors such as smoking, body mass index, and immunosuppressive therapy. Moreover, technical difficulties during the resection (snare or clip dysfunction) are associated with a delayed perforation (L. Zwager *et al.*, unpublished data). A potential explanation could be the thermal damage with subsequent tissue necrosis underneath the clip when an additional snare is used to resect the tissue after failed one-step EFTR.

Entrapment of adjacent organs into the cap leading to complications (such as enterocolonic fistulas) is a very rare event but can occur when extensive suction is used to incorporate the tissue into the cap.[8] Other rare complications include postpolypectomy syndrome, appendicitis (see below), colonic stenosis, and clip misplacement. While most AEs can be managed endoscopically or conservatively, the rate of AEs requiring surgical therapy is around 2%.[4,8]

Recurrence

Although there is a large body of evidence on efficacy and safety of colorectal EFTR, data on mid- and long recurrence is still lacking. The follow-up in most studies does not exceed 3–6 months. In the WALL RESECT study, the rate of residual or recurrent lesions in the group of "difficult adenomas" was 12.3% after 3 months.[8] Similarly, the German FTRD registry reported a rate of residual/recurrent lesions of 13.5% in a median follow-up of 22 weeks. Of these, 72% occurred after R1/Rx resection and 28% after R0 resection.[4] In contrast, in the Dutch FTRD registry the recurrence rate within 4 months was as low as 6.4%; however, follow-up data could only be obtained in 63.4%.[10]

There is little evidence on treatment of recurrent lesions after EFTR. As shown in several studies, the FTRD clip detaches spontaneously in about 70% of cases within 3 months. In case of clip retention, it can be removed using a bipolar cutting device to allow endoscopic retreatment.[16] Once the clip is removed, all endoscopic techniques including re-EFTR, EMR, ESD, or avulsion may be used, depending on lesion characteristics and local expertise. In both the WALL RESECT study and the German FTRD registry, recurrences could be successfully treated endoscopically in the majority of cases.[4,8]

EFTR for T1 carcinoma

Endoscopic full-thickness resection with the FTRD is increasingly used for diagnostic and therapeutic resection of colorectal T1 carcinomas. Current guidelines (American Society for Gastrointestinal Endoscopy,[17] European Society of Gastrointestinal Endoscopy[18]) recommend endoscopic resection of tumors fulfilling histological "low-risk" criteria (e.g., absence of poor differentiation, lymphatic or vascular invasion, deep submucosal invasion [>1000 μm], high grade tumor budding [grade 2 or 3], and a positive resection margin <1 mm [R1/Rx resection]) as an adequate therapy. Endoscopic treatment of such lesions is considered sufficient due to low risk of lymph node metastasis (LNM) (~1%) and the 5-year recurrence-free survival rate is >90% after complete endoscopic resection.[19–21] "High-risk" findings, on the other hand, should undergo operative resection and lymph node dissection due to the significantly increased risk of LNM (~20%) and the increased risk of local recurrence.[20,22–24]

In general, the exact pretherapeutic assignment to one of the two risk groups (low/high risk) is not possible with imaging and/or biopsy. Endoscopic full-thickness resection with the FTRD may be the ideal approach to achieve exact histological risk classification in the sense of a "diagnostic resection". On the other hand, it may be a minimally invasive therapy in case of low-risk tumors.

In a retrospective multicenter study by our group, 156 patients who underwent EFTR for early colorectal cancer were analyzed.[12] In 64 patients, EFTR was performed due to

© 2022 The Authors. *Digestive Endoscopy* published by John Wiley & Sons Australia, Ltd on behalf of Japan Gastroenterological Endoscopy Society.

incomplete (R1/Rx) resection of malignant polyps (group 1). The other 92 patients had EFTR for previously untreated nonlifting lesions (group 2). Histological discrimination between high- versus low-risk tumors was possible in 99.3%. In group 1, 84.1% of tumors were identified as low-risk lesions, and the rate of R0 resection was 87.5%. However, in the group of treatment-naïve lesions, only 16.3% were classified as low-risk. The R0 resection rate was also significantly lower (60.9%) in this group, indicating that too advanced lesions may have been selected for EFTR. A recent analysis from the Dutch colorectal EFTR registry included 330 procedures (198 scar resections and 132 primary resections).[10] Risk stratification was also possible in 99.3%. Overall, R0 resection and curative resection rates were 85.6% and 60.3%, respectively. The curative resection rate was 23.7% for primary resection of T1 colorectal cancer and 60.8% after excluding deep submucosal invasion as a risk factor. Additional oncological surgery was performed in 15.3% of cases, with residual cancer found in 22.4% of those. Both studies indicate that EFTR is an excellent technique for re-resection in case of R1/Rx resected T1 carcinomas.

Endoscopic full-thickness resection may also be a good option for treatment-naïve lesions. Recent studies have demonstrated that deep submucosal infiltration in the absence of other risk factors is associated with a low prevalence of LNM.[25,26] Hence, curative resection rates may further rise when stricter definitions of high-risk lesions are applied.

Moreover, for selected patients of a certain age or with comorbidities that do not allow surgical intervention, the FTRD system could be a potential definitive minimally invasive treatment alternative even in the presence of high-risk histology. However, long-term results are lacking and further studies are needed to further define optimal candidates for EFTR.

EFTR for SETs

Most larger studies on the efficacy and safety of EFTR include small subgroups of SETs and show favorable results concerning technical success and R0 resection.[4] In the German colonic FTRD registry, technical success was 97.3% and the R0 resection rate was significantly higher (97%) than that for other indications. A retrospective multicenter study on resection of rectal neuroendocrine tumors (NETs; $n = 40$) with the FTRD system also reported excellent results.[27] All lesions (median size 8 mm) could be resected macroscopically and histologically complete (100%) with a median procedure time of 18.5 min. No AEs were reported. A retrospective comparative analysis of transanal microsurgery versus EFTR showed no difference in en bloc resection rate, R0 resection rate, tumor size, or specimen size.[28] Although prospective comparative studies with other techniques are not available, these results indicate high efficacy of EFTR, especially for rectal NET.

EFTR for lesions at the appendiceal orifice

Endoscopic full-thickness resection for lesions at the appendiceal orifice has been suggested as an alternative to surgery. By pulling the lesion into the FTRD cap, the technique even allows resection of lesions with deep extension into the appendix.

In a retrospective multicenter study by Ichkhanian and colleagues, R0 resection rate was as high as 93% although 58% of lesions were deemed to have deep extension into the orifice.[7]

However, in a very similar German study the R0 rate was only 64%.[29] Reasons for this difference are not clear and future studies should aim to investigate risk factors for incomplete resection to allow a better patient selection. Although EFTR at the appendix seems to be feasible and effective, the procedure carries a significant risk of acute appendicitis.[30]

In the abovementioned studies, 15–17% of patients developed appendicitis and about half of these cases needed emergent appendectomy.[7,29] It is unclear why some patients develop appendicitis while others do not and criteria for selection of patients are still unknown. Moreover, apart from immediate adverse advents, possible long-term consequences of "clip-assisted" EFTR at the appendiceal orifice have not yet been evaluated. Therefore, patients should be thoroughly informed about the risks of the procedure and about treatment alternatives.

EFTR in patients with suspected motility disorders

Apart from therapeutic resections, EFTR can also be used to obtain full-thickness specimen of the intestinal wall in patients with suspected motility disorders. A novel modified device ("diagnostic FTRD") is available for such indications (Fig. 1). The system differs only marginally from the colorectal FTRD. It is slightly smaller in size and therefore captures less tissue in the cap. The system is suitable for endoscopes with a diameter of 10.5–12.0 mm and a working channel diameter of 3.2 mm. The cap diameter is 19.5 mm. Data on EFTR for diagnostic purposes is scarce. One study by Valli *et al*. showed that EFTR allows safe and minimally invasive harvesting of ample full-thickness tissue samples for accurate histological analysis in patients with suspicion

© 2022 The Authors. *Digestive Endoscopy* published by John Wiley & Sons Australia, Ltd on behalf of Japan Gastroenterological Endoscopy Society.

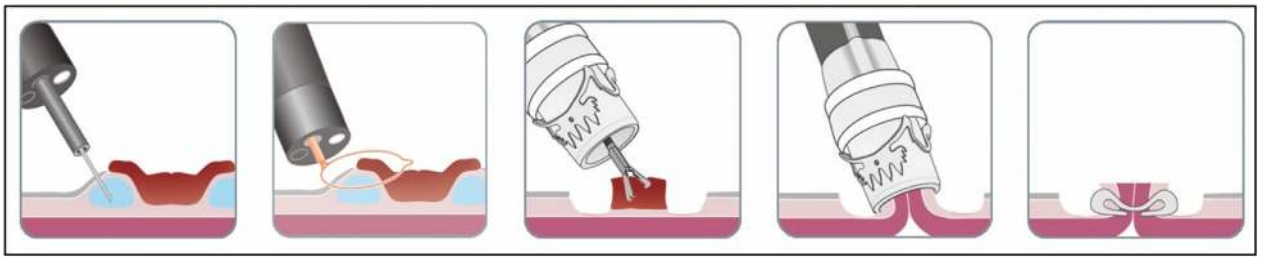

Figure 3 Schematic representation of hybrid full-thickness resection device procedure (left to right: circumferential injection and snare resection; central endoscopic full-thickness resection).

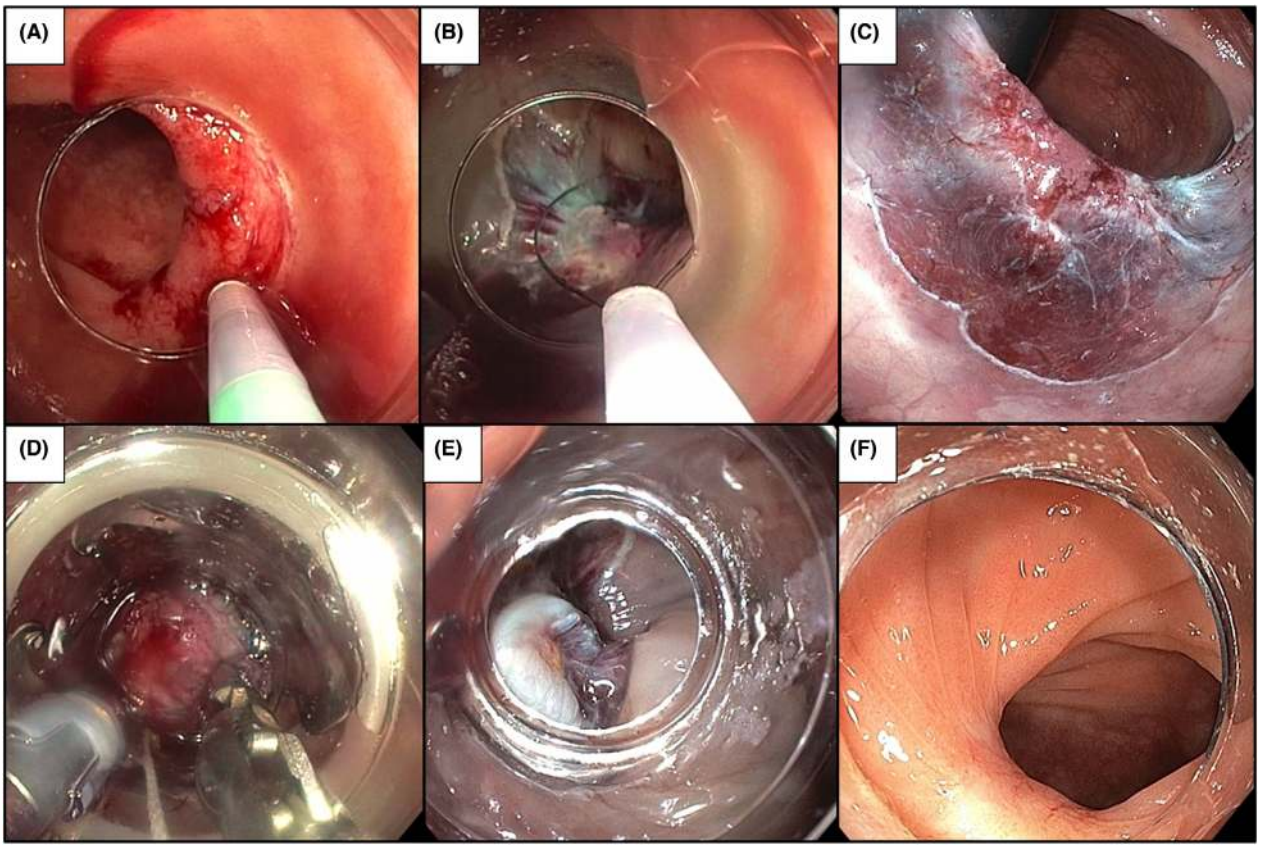

Figure 4 Hybrid full-thickness resection device (FTRD) procedure of a flat sigmoidal recurrent adenoma. (A) Circumferential injection. (B) Snare resection. (C) Central nonlifting part. (D) FTRD application. (E) Post-FTRD control. (F) 3-month endoscopic follow-up (no evidence of residual/recurrent adenoma).

of neuromuscular gut disorders such as Hirschsprung disease or enteric ganglionitis.[31]

HYBRID EFTR

THE MAIN LIMITATION of the FTRD system is the maximum size of the target lesion, which is determined by the size of the cap and the flexibility of the intestinal wall. Whereas in early animal studies resection specimens of up to 54 mm were described,[15] current clinical experience shows a safely resectable tumor size of maximum 30 mm for colorectal FTRD.[4]

The term "hybrid EFTR" or "hybrid FTRD" has been introduced to overcome the size limitation of resections with

© 2022 The Authors. *Digestive Endoscopy* published by John Wiley & Sons Australia, Ltd on behalf of Japan Gastroenterological Endoscopy Society.

the FTRD.[32] It is a combination of a conventional EMR followed by EFTR for the remaining lesion.

In a first step, the lifting lateral parts of the lesion are resected using the conventional piecemeal technique. Subsequently, the remaining nonlifting central portion of the lesion and EFTR with the FTRD is performed in the same session (Figs 3,4). This technique can also be applied to achieve complete resection for lesions which have primarily been attempted with EMR.

In the initial publication, 10 lesions with a diameter up to 50 mm were successfully resected with the hybrid approach without AEs and no recurrences within a 3-month follow-up.[32,33] A retrospective study comparing standalone EFTR and hybrid EFTR for colorectal lesions was recently published. These results revealed that the hybrid technique permitted resection of significantly larger lesions (mean, 39 mm; range, 15–70 mm) compared with standalone EFTR (mean, 17 mm; range, 7–25 mm; $P < 0.01$). Clinical success (91%), technical success (83%), and R0 resection (81%) rates did not differ between standalone and hybrid groups.[34] A recent series with 17 patients also reported favorable results.[35]

Endoscopic full-thickness resection can also be combined with ESD. In a study by Andrisani and colleagues, EFTR with the FTRD was used as a "rescue" procedure after ESD for lesions with severe fibrosis.[36]

The authors claim that this approach might increase complete resection rates and reduce complications in "difficult" ESD procedures.

In the hybrid technique, the FTRD clip naturally grasps only the seromuscular layers of the colonic wall. However, available studies do not show an increased rate of complications such as perforation or entrapment of adjacent tissue compared to the standalone technique.[34]

COLORECTAL EFTR IN COMPARISON WITH EMR AND ESD

THE TECHNICAL SUCCESS rate of colorectal EFTR is in line with the results of alternative resection techniques (EMR and ESD).[37] However, a direct comparison with EMR is difficult due to the difference in indications. While EFTR is mainly applied for nonlifting lesions such as recurrent adenomas, EMR is primarily used for treatment-naïve adenomas.[38] For recurrent nonlifting lesions, EMR has successfully been combined with avulsion and/or with thermal ablation.[39] To date it is not clear if EFTR is superior in the reduction of recurrences.

However, it is likely that it has significant advantages concerning histological work-up of the nonlifting parts of the lesions. A multicenter randomized controlled trial (RCT) comparing both techniques for resection of recurrent adenomas is currently recruiting (CURE study, DRKS 1200023539d) and results are not yet available.

Endoscopic submucosal dissection allows resection of larger lesions and is associated with higher en bloc resection and lower recurrence rates compared to EMR. However, it is technically demanding and time consuming. Moreover, there is a significantly increased risk of perforation, especially in the proximal colon.[40–42] Complete resection rates are highly dependent on expertise. While excellent R0 resection rates have been described in Asian studies,[43] early data from Western countries were less convincing.[44] In a prospective study from France, R0 resection for rectal lesions was achieved in only 53% ($n = 24$).[45]

However, many European centers have gained experience in the technique as shown by the recently published German ESD registry.[46] R0 resection rates in the rectum and colon were 80% and 72%, respectively. Hence, R0 rates of FTRD resection are in the range (or even higher) of those reported for Western ESD.

Although FTRD resection has more limitations in lesion size, it has the advantage that application in the colon (vs. rectum) is relatively easy and safe. However, comparative studies are not available.

EFTR IN THE UPPER GI TRACT

WITH THE INTRODUCTION of the gastroduodenal FTRD, a modified device is now available for use in the upper digestive tract (stomach and duodenum). The gastroduodenal FTRD is suitable for endoscopes having a diameter of 10.5–12.0 mm and a working channel diameter of 3.7 mm. The cap diameter is 19.5 mm and the cap depth is 23 mm. The system is thus slightly smaller compared to the colorectal FTRD. The set includes a 20 mm balloon to facilitate passage through the upper esophageal sphincter and pylorus if needed (Fig. 1).

Several studies on FTRD in the upper digestive tract were conducted prior to the launch of the gastroduodenal device. First successful case reports were already published in 2015.[47] A retrospective evaluation of 20 off-label applications in the duodenum (indications: 13 adenomas, five SETs, and one T1 adenocarcinoma) was reported in 2018. Resection was technically successful in 85% ($n = 17$).

However, the R0 resection rate of 63% ($n = 12$) was surprisingly low. This was most likely due to the fact that too advanced lesions were selected for en bloc EFTR (mean diameter, 17 mm; range, 5–35 mm). In about 16% ($n = 3$) minor AEs occurred; no major AE was reported.[48]

The RESET study was the first prospective multicenter clinical study investigating EFTR of gastric SETs with the

© 2022 The Authors. *Digestive Endoscopy* published by John Wiley & Sons Australia, Ltd on behalf of Japan Gastroenterological Endoscopy Society.

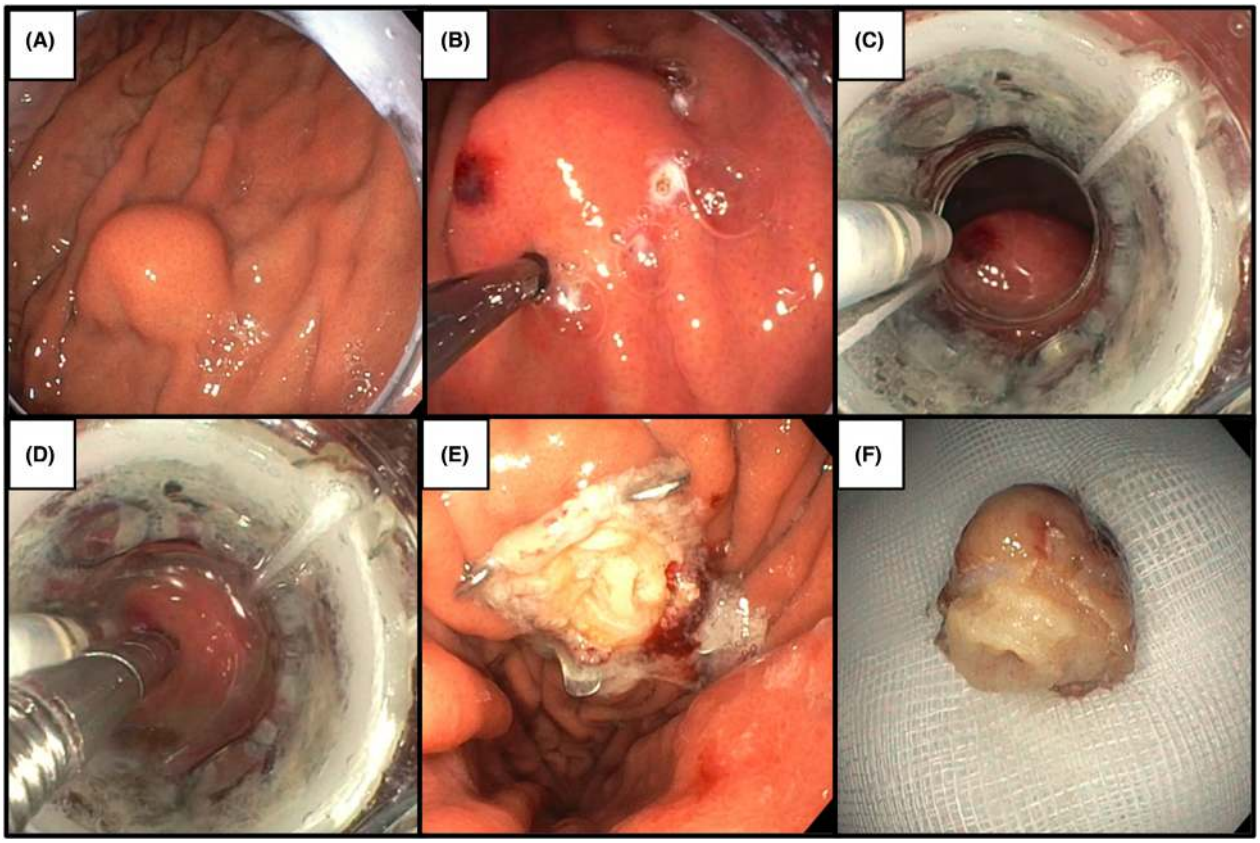

Figure 5 Full-thickness resection of a gastral 15 × 11 mm subepithelial tumor (SET). (A) Exophytic lesion in gastric corpus. (B) Circumferential marking using the full-thickness resection device (FTRD) marking probe. (C) Mounted FTRD. (D) Insertion of SET into the cap using an endoscopic anchor. (E) Applied clip. (F) Macroscopically complete resected SET.

FTRD. The study included 29 subepithelial gastric lesions with a median size of 11 mm (range, 5–15 mm).[49] Technical success rate was 89.7%, R0 resection rate was reached in 76% of cases. Median procedure time was 36.3 min with no major AEs reported. EFTR allowed definitive histological diagnosis including risk classification in cases of GI stroma tumors or NETs. Figure 5 shows the EFTR of a gastric SET.

The largest multicenter retrospective analysis to date on the use of the FTRD system in the upper digestive tract analyzed the use of 56 EFTRs (stomach, n = 47; duodenum, n = 8; and esophagus, n = 1).[50]

A high rate of technically successful resections (93%, n = 52) was demonstrated. The R0 resection rate in the evaluation was 68% (n = 38). In about 21% (n = 12) minor AEs were reported, no major AEs occurred.

In view of the current data (Table 2), EFTR in the upper digestive tract seems feasible and effective for diagnostic and therapeutic resection of small (≤15 mm) SETs in the stomach. Modification of the technique, such as combination with prior circumferential incision have been described and are currently further investigated in prospective studies (STREET study, NCT04913077).

Apart from subepithelial lesions, it can also be applied for duodenal adenomas. However, data on this indication are scarce and it is unclear if EFTR should only be restricted to nonlifting lesions or if it also should be applied for treatment-naïve adenomas (with the intention to reduce late bleeding and recurrency rates). Results of an ongoing RCT (DUO RESECT study, NCT03559231) comparing EFTR with EMR are still pending.

SUMMARY AND CONCLUSION

ENDOSCOPIC FULL-THICKNESS RESECTION with the FTRD allows safe and efficient treatment of lesions not amenable to conventional endoscopic techniques. The procedure is relatively simple and requires less training compared to other advanced resection techniques; it has

© 2022 The Authors. *Digestive Endoscopy* published by John Wiley & Sons Australia, Ltd on behalf of Japan Gastroenterological Endoscopy Society.

Table 2 Gastroduodenal full-thickness resection device (FTRD) literature

Study	Study type	Total FTRD cases, *N*	Type of lesion	Technical success, %	R0 resection, %	Total AEs (major AEs) %
Schmidt *et al.* (2015)[47]	Case report	4	Nonlifting adenoma (2), SET (2)	100.0	75.0	50.0 (0)
Meier *et al.* (2020)[49]	Prospective	29	SET (29)	89.7	76.0	31.0 (0)
Hajifathalian *et al.* (2020)[50]	Retrospective multicenter	56	Mesenchymal neoplasm including GIST (26), diagnostic (10), NET (9), adenoma (6), adenocarcinoma (5)	93.0	68.0	21.0 (0)

AE, adverse event; GIST, gastrointestinal stroma tumor; NET, neuroendocrine tumor; SET, subepithelial tumor.

therefore rapidly entered clinical routine. Apart from therapy, it also allows an exact histological workup including risk stratification in case of malignant tumors. Developments in device design and combination with other resection techniques such as EMR and ESD have further expanded the indications. While there is a broad body of evidence showing efficacy and safety in the colorectum, data on EFTR in the upper GI tract are still scarce.

Future studies should also aim to further develop criteria for optimal patient selection, to evaluate long-term outcomes, and to compare EFTR with conventional resection techniques like EMR or ESD.

ACKNOWLEDGMENT

OPEN ACCESS FUNDING enabled and organized by Projekt DEAL.

CONFLICT OF INTEREST

AUTHORS A.K. AND A.S. have received study grants and honoraria for lectures from Ovesco Endoscopy. The other authors declare no conflict of interest for this article.

FUNDING INFORMATION

NONE.

REFERENCES

1 Fujiya M, Tanaka K, Dokoshi T *et al*. Efficacy and adverse events of EMR and endoscopic submucosal dissection for the treatment of colon neoplasms: A meta-analysis of studies comparing EMR and endoscopic submucosal dissection. *Gastrointest Endosc* 2015; **81**: 583–95.

2 Schurr MO, Baur F, Ho CN, Anhoeck G, Kratt T, Gottwald T. Endoluminal full-thickness resection of GI lesions: A new device and technique. *Minim Invasive Ther Allied Technol* 2011; **20**: 189–92.

3 Andrisani G, Soriani P, Manno M *et al*. Colo-rectal endoscopic full-thickness resection (EFTR) with the over-the-scope device (FTRD®): A multicenter Italian experience. *Dig Liver Dis* 2019; **51**: 375–81.

4 Meier B, Stritzke B, Kuellmer A *et al*. Efficacy and safety of endoscopic full-thickness resection in the colorectum: Results from the German colonic FTRD registry. *Am J Gastroenterol* 2020; **115**: 1998–2006.

5 Krutzenbichler I, Dollhopf M, Diepolder H *et al*. Technical success, resection status, and procedural complication rate of colonoscopic full-wall resection: A pooled analysis from 7 hospitals of different care levels. *Surg Endosc* 2021; **35**: 3339–53.

6 Brewer Gutierrez OI, Akshintala VS, Ichkhanian Y *et al*. Endoscopic full-thickness resection using a clip non-exposed method for gastrointestinal tract lesions: A meta-analysis. *Endosc Int Open* 2020; **8**: E313–25.

7 Ichkhanian Y, Barawi M, Seoud T *et al*. Endoscopic full-thickness resection of polyps involving the appendiceal orifice: A multicenter international experience. *Endoscopy* 2022; **54**: 16–24.

8 Schmidt A, Beyna T, Schumacher B *et al*. Colonoscopic full-thickness resection using an over-the-scope device: A prospective multicentre study in various indications. *Gut* 2018; **67**: 1280–9.

9 Kuellmer A, Behn J, Beyna T *et al*. Endoscopic full-thickness resection and its treatment alternatives in difficult-to-treat lesions of the lower gastrointestinal tract: A cost-effectiveness analysis. *BMJ Open Gastroenterol* 2020; **7**: e000449.

10 Zwager LW, Bastiaansen BAJ, van der Spek BW *et al*. Endoscopic full-thickness resection of T1 colorectal cancers: A retrospective analysis from a multicenter Dutch eFTR registry. *Endoscopy* 2022; **54**: 475–85.

11 Dolan RD, Bazarbashi AN, McCarty TR, Thompson CC, Aihara H. Endoscopic full-thickness resection of colorectal lesions: A systematic review and meta-analysis. *Gastrointest Endosc* 2022; **95**: 216–24.e18.

© 2022 The Authors. *Digestive Endoscopy* published by John Wiley & Sons Australia, Ltd on behalf of Japan Gastroenterological Endoscopy Society.

12 Kuellmer A, Mueller J, Caca K *et al*. Endoscopic full-thickness resection for early colorectal cancer. *Gastrointest Endosc* 2019; **89**: 1180–9.
13 Zwager LW, Bastiaansen BAJ, Bronzwaer MES *et al*. Endoscopic full-thickness resection (eFTR) of colorectal lesions: Results from the Dutch colorectal eFTR registry. *Endoscopy* 2020; **52**: 1014–23.
14 Didden P, van Eijck van Heslinga RAH, Schwartz MP *et al*. Relevance of polyp size for primary endoscopic full-thickness resection of suspected T1 colorectal cancers. *Endoscopy* Published online: 23 Jun 2022; DOI: 10.1055/a-1790-5539.
15 Schurr MO, Baur FE, Krautwald M *et al*. Endoscopic full-thickness resection and clip defect closure in the colon with the new FTRD system: Experimental study. *Surg Endosc* 2015; **29**: 2434–41.
16 Bauder M, Meier B, Caca K, Schmidt A. Endoscopic removal of over-the-scope clips: Clinical experience with a bipolar cutting device. *United European Gastroenterol J* 2017; **5**: 479–84.
17 Kaltenbach T, Anderson JC, Burke CA *et al*. Endoscopic removal of colorectal lesions – Recommendations by the US Multi-Society Task Force on colorectal cancer. *Gastrointest Endosc* 2020; **91**: 486–519.
18 Pimentel-Nunes P, Dinis-Ribeiro M, Ponchon T *et al*. Endoscopic submucosal dissection: European Society of Gastrointestinal Endoscopy (ESGE) guideline. *Endoscopy* 2015; **47**: 829–54.
19 Yoda Y, Ikematsu H, Matsuda T *et al*. A large-scale multicenter study of long-term outcomes after endoscopic resection for submucosal invasive colorectal cancer. *Endoscopy* 2013; **45**: 718–24.
20 Bosch SL, Teerenstra S, de Wilt JHW, Cunningham C, Nagtegaal ID. Predicting lymph node metastasis in pT1 colorectal cancer: A systematic review of risk factors providing rationale for therapy decisions. *Endoscopy* 2013; **45**: 827–34.
21 Ikematsu H, Yoda Y, Matsuda T *et al*. Long-term outcomes after resection for submucosal invasive colorectal cancers. *Gastroenterology* 2013; **144**: 551–9.
22 Nascimbeni R, Burgart LJ, Nivatvongs S, Larson DR. Risk of lymph node metastasis in T1 carcinoma of the colon and rectum. *Dis Colon Rectum* 2002; **45**: 200–6.
23 Choi JY, Jung SA, Shim KN *et al*. Meta-analysis of predictive clinicopathologic factors for lymph node metastasis in patients with early colorectal carcinoma. *J Korean Med Sci* 2015; **30**: 398–406.
24 Suh JH, Han KS, Kim BC *et al*. Predictors for lymph node metastasis in T1 colorectal cancer. *Endoscopy* 2012; **44**: 590–5.
25 Yasue C, Chino A, Takamatsu M *et al*. Pathological risk factors and predictive endoscopic factors for lymph node metastasis of T1 colorectal cancer: A single-center study of 846 lesions. *J Gastroenterol* 2019; **54**: 708–17.
26 Zwager LW, Bastiaansen BAJ, Montazeri NSM *et al*. Deep submucosal invasion is not an independent risk factor for lymph node metastasis in T1 colorectal cancer: A meta-analysis. *Gastroenterology* 2022; **163**: 174–89.
27 Meier B, Albrecht H, Wiedbrauck T, Schmidt A, Caca K. Full-thickness resection of neuroendocrine tumors in the rectum. *Endoscopy* 2020; **52**: 68–72.
28 Brand M, Reimer S, Reibetanz J, Flemming S, Kornmann M, Meining A. Endoscopic full thickness resection vs. transanal endoscopic microsurgery for local treatment of rectal neuroendocrine tumors – A retrospective analysis. *Int J Colorectal Dis* 2021; **36**: 971–6.
29 Schmidbaur S, Wannhoff A, Walter B *et al*. Risk of appendicitis after endoscopic full-thickness resection of lesions involving the appendiceal orifice: A retrospective analysis. *Endoscopy* 2021; **53**: 424–8.
30 Schmidt A. Lesions at the appendiceal orifice – The Achilles' heel of endoscopic resection? *Endoscopy* 2022; **54**: 25–6.
31 Valli PV, Pohl D, Fried M, Caduff R, Bauerfeind P. Diagnostic use of endoscopic full-thickness wall resection (eFTR) – A novel minimally invasive technique for colonic tissue sampling in patients with severe gastrointestinal motility disorders. *Neurogastroenterol Motil* 2018; **30**: e13153
32 Meier B, Caca K, Schmidt A. Hybrid endoscopic mucosal resection and full-thickness resection: A new approach for resection of large non-lifting colorectal adenomas (with video). *Surg Endosc* 2017; **31**: 4268–74.
33 Lupu A, Jacques J, Rivory J *et al*. Hybrid endoscopic submucosal dissection using a full-thickness resection device allows en bloc resection of a large adenoma deeply invading the appendix. *Endoscopy* 2018; **50**: E296–8.
34 Mahadev S, Vareedayah AA, Yuen S, Yuen W, Koller KA, Haber GB. Outcomes of a hybrid technique using EMR and endoscopic full-thickness resection for polyps not amenable to standard techniques (with video). *Gastrointest Endosc* 2021; **94**: 358–67.e1.
35 Bauermeister M, Mende M, Hornoff S, Faiss S. Hybrid resection of large colorectal adenomas combining EMR and FTRD. *Scand J Gastroenterol* 2021; **56**: 978–83.
36 Andrisani G, Di Matteo FM. Hybrid resection with ESD and FTRD: Could this be a rescue treatment in the presence of severe submucosal fibrosis? *Dig Liver Dis* 2019; **51**: 607–9.
37 Hassan C, Repici A, Sharma P *et al*. Efficacy and safety of endoscopic resection of large colorectal polyps: A systematic review and meta-analysis. *Gut* 2016; **65**: 806–20.
38 Holmes I, Friedland S. Endoscopic mucosal resection versus endoscopic submucosal dissection for large polyps: A Western colonoscopist's view. *Clin Endosc* 2016; **49**: 454–6.
39 Tate DJ, Bahin FF, Desomer L, Sidhu M, Gupta V, Bourke MJ. Cold-forceps avulsion with adjuvant snare-tip soft coagulation (CAST) is an effective and safe strategy for the management of non-lifting large laterally spreading colonic lesions. *Endoscopy* 2018; **50**: 52–62.
40 Hong SN, Byeon JS, Lee BI *et al*. Prediction model and risk score for perforation in patients undergoing colorectal endoscopic submucosal dissection. *Gastrointest Endosc* 2016; **84**: 98–108.

© 2022 The Authors. *Digestive Endoscopy* published by John Wiley & Sons Australia, Ltd on behalf of Japan Gastroenterological Endoscopy Society.

41 Sato K, Ito S, Kitagawa T *et al*. Factors affecting the technical difficulty and clinical outcome of endoscopic submucosal dissection for colorectal tumors. *Surg Endosc* 2014; **28**: 2959–65.
42 Mizushima T, Kato M, Iwanaga I *et al*. Technical difficulty according to location, and risk factors for perforation, in endoscopic submucosal dissection of colorectal tumors. *Surg Endosc* 2015; **29**: 133–9.
43 Asayama N, Oka S, Tanaka S, Hayashi N, Arihiro K, Chayama K. Endoscopic submucosal dissection as total excisional biopsy for clinical T1 colorectal carcinoma. *Digestion* 2015; **91**: 64–9.
44 Sauer M, Hildenbrand R, Oyama T, Sido B, Yahagi N, Dumoulin FL. Endoscopic submucosal dissection for flat or sessile colorectal neoplasia >20 mm: A European single-center series of 182 cases. *Endosc Int Open* 2016; **4**: E895–900.
45 Rahmi G, Hotayt B, Chaussade S *et al*. Endoscopic submucosal dissection for superficial rectal tumors: Prospective evaluation in France. *Endoscopy* 2014; **46**: 670–6.
46 Fleischmann C, Probst A, Ebigbo A *et al*. Endoscopic submucosal dissection in Europe: Results of 1000 neoplastic lesions from the German endoscopic submucosal dissection registry. *Gastroenterology* 2021; **161**: 1168–78.
47 Schmidt A, Meier B, Cahyadi O, Caca K. Duodenal endoscopic full-thickness resection (with video). *Gastrointest Endosc* 2015; **82**: 728–33.
48 Bauder M, Schmidt A, Caca K. Endoscopic full-thickness resection of duodenal lesions – A retrospective analysis of 20 FTRD cases. *United European Gastroenterol J* 2018; **6**: 1015–21.
49 Meier B, Schmidt A, Glaser N *et al*. Endoscopic full-thickness resection of gastric subepithelial tumors with the gFTRD-system: A prospective pilot study (RESET trial). *Surg Endosc* 2020; **34**: 853–60.
50 Hajifathalian K, Ichkhanian Y, Dawod Q *et al*. Full-thickness resection device (FTRD) for treatment of upper gastrointestinal tract lesions: The first international experience. *Endosc Int Open* 2020; **8**: E1291–301.

© 2022 The Authors. *Digestive Endoscopy* published by John Wiley & Sons Australia, Ltd on behalf of Japan Gastroenterological Endoscopy Society.